B-ENT, 2016, **12**, Suppl. 26/1, 173-183

Middle ear damages

H. Van Hoecke; L. Calus; I. Dhooge

Department of Otorhinolaryngology, Ghent University Hospital, Ghent, Belgium

Key-words. Middle ear; trauma; tympanic membrane perforation; ossicular chain

Abstract. *Middle ear damages*. The eardrum and middle ear are often exposed to blunt and penetrating trauma, blasts, thermal or caustic injuries. These injuries may result in tympanic membrane perforation, middle ear haemorrhage, dislocation and fracture of the ossicular chain, perilymphatic fistula and damage to the chorda tympani and/or facial nerve. In case of life-threatening injuries and/or mass casualty incidents, middle ear trauma obviously does not take highest priority. However, middle ear lesions should be suspected and recognized as early as possible. After meticulous history taking, physical examination consists of cranial nerve evaluation, thorough inspection of the outer ear, otoscopy and assessment of hearing and vestibular function.

In the majority of cases, traumatic tympanic membrane perforations by penetrating and blunt injuries have a good prognosis with spontaneous resolution. Tympanic membrane perforations from blast trauma, thermal or caustic injuries are less likely to heal spontaneously. Perforations lasting six months after injury warrant surgery. A high resolution CT scan of the temporal bone is required in case of immediate complete facial nerve paralysis and when oval window pathology or perilymphatic fistula is suspected. Early surgical intervention is needed in case of early onset facial nerve paralysis, when there is suspicion of a perilymphatic fistula with persisting or increasing vestibular symptoms or neurosensory hearing loss and in case of vestibular dislocation of the stapes footplate. When ossicular chain damage is suspected, elective tympanoplasty is indicated. As any traumatic tympanic membrane perforation runs the risk of cholesteatoma formation, biannual follow-up during a minimum of two years is recommended.

Introduction

Although middle ear trauma is not the first priority in the context of life-threatening injuries, the ear is particularly susceptible to damage and easily forgotten in patients with multiple injuries. Traumatic lesions of the middle ear should be suspected and recognized as early as possible. Otologic evaluation should take place as soon as medical circumstances permit, as therapeutic intervention within 24 hours leads to the quicker and fuller recovery of function.[1]

In this chapter we address blunt and penetrating trauma, blast injuries and thermal or caustic injuries of the middle ear. We provide clinical guidance for early assessment, further diagnosis, treatment and follow-up.

For middle ear trauma caused by barotrauma other than blast injuries, we refer to Chapter 14. Middle ear damage in the context of temporal bone fractures are also discussed in Chapter 13. For the management of traumatic external ear lesions, we refer to Chapter 10.

Blunt and penetrating trauma of the middle ear

Introduction

Temporal bone trauma is usually the result of a blunt head injury and patients commonly suffer from concurrent intracranial, cervical spine or multiple other body injuries.[2] Blunt head injuries are primarily caused by motor vehicle accidents, followed by non-motor vehicle traffic accidents, falls and physical aggression. While temporal bone trauma related to traffic accidents have decreased over the past number of years, injuries from physical assaults show an alarming increase, especially in large urban populations.[3] Middle ear structures can also be damaged by penetrating or concussive trauma such as a hand blow to the pinna.

Direct trauma to the tympanic membrane and middle ear is seen primarily in children.[4] Common instruments for direct trauma injury include pencils, cotton-tipped swabs, matchstick and hairpins.

Iatrogenic perforation can occur during ear irrigation or foreign body removal.

Gunshot wounds to the head are an unusual aetiology of temporal bone trauma, but are increasing in frequency and are associated with a much higher risk of major complications and mortality, due to injury to the brain tissue and important vascular structures in the head.[5] In the case of an explosion, pressure-driven projectiles can also enter the ear.

Blunt and penetrating injuries of the middle ear may result in tympanic membrane perforation, middle ear haemorrhage, dislocation and fracture of the ossicular chain, perilympatic fistula from the oval or round window, injury to the chorda tympani and/or facial nerve injury.

Pre-hospital assessment (fact sheet)

In case of life-threatening injuries and/or mass casualty incidents, (middle) ear trauma does not take high priority.

In the initial evaluation of serious head trauma or polytrauma, stabilization must first be accomplished. Airway management, evaluation of neurological status, haemorrhage, open fractures and abdominal and chest injuries may delay early diagnosis and treatment of temporal bone injuries. The cervical spine should be evaluated and stabilized before the head is manipulated. Otolaryngologists are typically not members of the initial team that evaluates and treats a patient with a head injury, but pre-hospital care providers and emergency physicians should be trained to assess the status of the external ear canal (checking for blood or liquorrhoea), the status of the facial nerve and question symptoms of hearing loss and vertigo in a conscious patient.

The severity of the injury determines whether the trauma is minor enough to be handled in an office setting or whether the operating room is required for management.

Hospital assessment and early evaluation (fact sheet)

As soon as clinical circumstances permit, every patient with a middle ear or temporal bone trauma should undergo a complete neuro-otologic examination, including a hearing evaluation. In the context of severe head trauma or polytrauma, an initial assessment must be performed by the physicians first involved (emergency physicians, neurologists and neurosurgeons), with subsequent otorhinolaryngologic referral.

Patient history should focus on the mechanism of injury and pre-existing deficits such as a perforated eardrum or hearing loss. In a conscious patient, symptoms of earache, hearing loss, ear fullness, tinnitus and/or vertigo must be questioned. Traumatic perforation of the tympanic membrane causes sudden and severe pain, sometimes followed by bleeding from the ear, hearing loss and tinnitus. Hearing loss is more severe if the ossicular chain is disrupted or the inner ear is injured. Vertigo suggests a perilymphatic fistula or injury to the inner ear. Purulent otorrhoea may begin in 24 to 48 hours, particularly if water or foreign bodies have entered the middle ear.

Physical examination consists of a cranial nerve examination, thorough inspection of the outer ear, otoscopy, assessment of the hearing and vestibular function.

The first priority is to examine the full extent of the injury. Attention should be paid to external signs of ear injury such as discharge or bleeding from the ear canal, penetrating trauma or burns of the outer ear, as well as facial nerve palsy. Retroauricular haematoma (battle sign) can occur after 24 to 48 hours and is suggestive of a skull base fracture. Otoscopy and preferentially microscopic otoscopy, is needed to inspect the outer ear canal and to remove eventual foreign bodies like blood and glass in order to have a clear view of the tympanic membrane and middle ear. The presence of a tympanic membrane perforation, blood or fluid in the middle ear – which may be suggestive of a cerebrospinal fluid leak or perilymphatic fistula – is evaluated.

The majority of tympanic membrane perforations following blunt or penetrating trauma are located in the antero-inferior pars tensa region.[1] Early management of tympanic membrane perforation consists of keeping the ear dry and clean. Routine antibiotic eardrops are unnecessary. However, prophylaxis with oral broad-spectrum antibiotics or antibiotic eardrops is necessary in contaminated cases or injuries that have occurred during water activities. The patient is instructed to avoid nose blowing, sneezing and exposure to water. Alignment of the perforation marges and subsequent patching, e.g., with moistened cigarette paper or silastic or gelatin foam or film has been reported by some authors to prevent inversion of the perforation edges

and to promote prompt healing; other studies, however, could not confirm this. [6-13] (see Figure 1)

A traumatic perforation in the posterosuperior quadrant can particularly be associated with ossicular chain disruption. Ossicular chain dislocations are much more common than ossicular chain fractures and can occur in association with a traumatic eardrum perforation, but can also occur without tympanic membrane perforation. The most common ossicular chain lesion following blunt or penetrating middle ear trauma is incudostapedial joint separation. The malleoincudal joint is better protected by the epitympanic recess, but its dislocation accounts for the second most traumatic ossicular chain lesion. The incus, the heaviest of the three middle ear ossicles, is only suspended by rather weak ligaments and is more easily dislocated than the more firmly attached malleus and stapes (see Figure 2). In cases of trauma, the malleus, the attachment of which is guaranteed by the tympanic membrane, the anterior and lateral ligaments of the malleus and the tensor muscle and tendon generally remains in position or move slightly. The stapes is firmly attached to the oval window by the annular stapedial ligament; however, traumatic luxation of the stapes into the vestibulum can occur, particularly following penetrating injuries through the posterosuperior tympanic membrane. Fractures of the ossicles are rarer, but can occur anywhere along the ossicular chain. In order of appearance, displaced or non-displaced fractures of the long process of the incus, the stapes crurae, the stapes footplate and the malleus handle can occur. Fracture or vestibular dislocation of the stapes footplate can lead to abnormal communication between the middle and the inner ear, allowing air to enter the vestibule and inner ear through the oval window (pneumolabyrinth), as well as leakage of perilymph fluid into the middle ear (perilymphatic fistula) (see further).[14-16]

Early assessment of the nature of hearing loss can be performed via tuning fork tests. Following blunt or penetrating temporal trauma to the ear, hearing loss can be conductive, mixed or sensorineural. All patients should undergo a complete audiogram to determine the exact extent and nature of the hearing loss if possible, both prior to and following treatment, in order to avoid confusion between trauma-induced and treatment-induced hearing loss. In the case of tympanic membrane perforation, hearing loss is the result of a decreased drum area, resulting in conductive hearing loss, which increases alongside an increase in size of the perforation.[17] A conductive component of at least 30 dB, however, indicates possible ossicular discontinuity.

Vestibular symptoms after blunt or penetrating trauma with or without temporal bone fractures

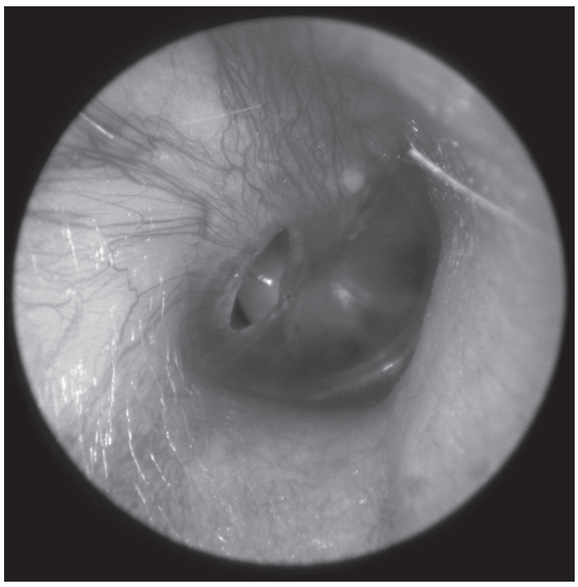

Figure 1
Tympanic membrane perforation by penetrating trauma

Figure 2
Incus dislocation into the outer ear canal after blunt trauma with temporal bone fracture

are suggestive for a perilymphatic fistula or labyrinthine lesions. Other causes of posttraumatic vertigo such as benign paroxysmal positional vertigo should be excluded. A traumatic perforation in the posterosuperior quadrant of the tympanic membrane with persistent, severe vertigo and nystagmus suggests stapedial trauma. Common presenting symptoms of a perilymphatic fistula include vertigo, disequilibrium, sensorineural or mixed hearing loss – which can vary from sudden and profound to mild and fluctuating – tinnitus, aural fullness, hyperacousis and headache.[18,19] Sometimes, the leaking perilymph can be seen upon otoscopy as middle ear effusion. A fistula test, comprising the recording of eye movements while pressurizing the ear canal with a small rubber bulb can be useful, but is not advisable to perform in patients with a traumatic tympanic membrane perforation. Although rarely encountered, as it requires a very large fistula and a rapid CT scan of the ear, air in the labyrinth (pneumolabyrinth) is a radiological finding of a (recent) fistula.

Perilymphatic fistulas are believed to heal spontaneously in a number of cases. Most authors recommend initially treating patients with bed rest, head elevation, to use stool softeners and anti-emetics, avoid the Valsalva manoeuvre and to reserve surgical exploration and fistula repair for patients with persisting vestibular symptomatology and progressive sensorineural hearing loss. However, some recommend initial surgical management in the hope of achieving earlier resolution of vestibular symptoms and the prevention of the progression of sensorineural hearing loss.[20,21] We recommend initial conservative management with early (within 1-2 weeks) exploratory tympanotomy and fistula repair in case of persisting or increasing vestibular symptoms or neurosensory hearing loss. Following fistula repair, early and complete resolution of vestibular symptoms is obtained in the vast majority of cases; however, the effects on sensorineural hearing loss are inconsistent, with reports varying from important recovery to minimal or even no improvement in hearing loss. [20,22]

Facial paresis (weakness) or paralysis and facial asymmetry in association with middle ear trauma are indicative of injury to the facial nerve. The timing of onset (immediate or delayed) and the characteristics (complete or incomplete paralysis) of symptoms are an important factor in the planning of treatment; therefore, early assessment and scoring of the facial nerve functioning is crucial. Following initial examination and stabilization, patients with significant trauma may be sedated or comatose, which often complicates further evaluation of facial nerve functioning. Facial response to a painful stimulus may be helpful in patients who are unable to cooperate or have altered mental status. In cases of immediate or early onset (within hours following trauma) facial nerve paralysis, early surgical intervention is often needed. However, early onset can easily go unnoticed by patients due to facial swelling, lacerations and abrasions. For a more detailed diagnostic and therapeutic approach to facial nerve injury secondary to lateral skull base trauma, we refer to Chapter 13.

A high resolution CT scan of the skull is necessary in all cases of major trauma to the skull in order to determine the extent of the trauma and concomitant neurovascular injury. In case of suspected oval window pathology or perilymphatic fistula, imaging studies should be performed without delay.

Long-term follow-up, treatment and prognosis of blunt and penetrating injuries of the middle ear (fact sheet)

Overall, traumatic tympanic membrane perforations have excellent prognosis. The spontaneous healing rate appears to be close to 80% in traumatic tympanic membrane perforations, occurring within three months.[23] The most determining factor for spontaneous closure is perforation size.[24,25] Small perforations have a high probability of spontaneous closure within weeks, while large or subtotal perforations have a significantly reduced closure rate and may warrant surgical repair. Marginal perforation, pre-existing tympanosclerosis and a perforation that involves the malleus or umbo are negative prognostic factors.[25,26]

It is suggested that the phenotype of perforation edges may also be a prognostic indicator of healing outcomes. The presence of granulation tissue and oedema appear to indicate a better prognosis.[24,27]

Otomicroscopic and audiometric follow-up at regular intervals (six weeks, three months and six months after trauma) is advisable. Tympanic perforation lasting six months after injury warrants surgery.

Persistent conductive hearing loss of 30 decibels or more, or conductive hearing loss lasting for two months after healing of the tympanic membrane

and restored middle ear ventilation is indicative of ossicular injury.[28] Ossicular chain dislocation with an intact eardrum will manifest as a maximal (60 dB) conductive hearing loss. Ossicular chain dislocation with a perforated eardrum will have lesser degrees of hearing loss. A high resolution CT scan can indicate the site and type of ossicular lesion(s) but is not always conclusive and exploratory tympanotomy remains the gold standard in this case. Treatment of hearing loss due to ossicular chain disruption consists of ossicular chain reconstruction or hearing aid amplification. Some authors advocate not delaying tympanotomy more than three to six months following middle ear trauma, as delayed cases are assumed to be associated with more adhesion, fibrosis and tympanosclerosis. There is, however, no conclusive proof that early tympanotomy and ossiculoplasty promotes a better outcome.[28] Both early and delayed surgical intervention have shown satisfying results, which primarily depend on the type and extensiveness of the trauma and the skills of the surgeon, rather than on the timing of surgery; tympanotomy can reasonably be delayed until the patient is ready to undergo this procedure.

A late complication after blunt or penetrating trauma is the delayed development of cholesteatoma (see also paragraph blast injuries). It is essential to plan a clinical follow-up every six months for a minimum of two years and some authors advise performing standard imaging (diffusion weighted MRI) one-to-two years after an extensive traumatic injury to the middle ear.

Blast injury of the middle ear

Introduction

Blast injuries are a complex type of physical trauma caused by direct or indirect exposure to explosions and can result from various types of incidents, ranging from fireworks-related explosions and industrial accidents to terrorist attacks.[29] High-order explosives have the capability to cause multisystem, life-threatening injuries in single or multiple victims simultaneously. These types of events present challenging triage, diagnostic and management strategies.

Blast injuries are generally categorized as ranging from primary to quaternary: primary injuries are caused by the direct effect of blast overpressure waves on tissue; secondary injuries are caused by projectiles from bomb fragments and flying objects that can result in blunt and penetrating trauma; tertiary injuries occur when high-energy explosions create a blast wind, displacing victims through the air against solid objects and leading to a combination of blunt and penetrating trauma; quaternary injuries encompass all other injuries caused by explosions including burns, crush and toxic injuries, as well as noise induced hearing loss.[30]

The magnitude of damage due to the blast wave depends on the type of explosive material, the distance from the source, the medium in which it explodes and the shock wave reflection within the confined area.[31] Air-containing structures such as the middle ear, the lungs and the gastro-intestinal tract are at highest risk for primary blast injuries, due to the rapid changes in velocity of the blast wave at air-tissue interfaces. Over-pressurization in high-energy explosions can produce injuries that may have no obvious external signs of trauma. Blast lung injury is the most common cause of death in initial survivors, but traumatic brain injuries can also present without signs of external trauma and merit immediate attention.[32]

The ear is designed to efficiently transmit pressure waves and is the organ most vulnerable to primary blast injury. Tympanic membrane perforation is the most common primary blast injury, occurring in 8-61% of patients exposed to serious blast events, but the delicate middle ear ossicles and inner ear structures can also easily be damaged.[33-35] Facial nerve paresis or paralysis is a rare primary blast injury caused by barotrauma as the result of compression of the nerve along its trajectory in the middle ear and occurs mainly in case of a pre-existing bony dehiscence of the facial nerve canal.[36]

The presence of tympanic membrane rupture indicates that a high-pressure wave (at least 40 kilopascal [kPa]) had been present and may correlate with more dangerous organ injuries. Theoretically, at an overpressure of 100 kPa, the threshold for lung injury, the tympanic membrane routinely ruptures. However, more recent data contradict traditional beliefs about a clear correlation between the presence of tympanic membrane injury and coincident organ damage. In the absence of other symptoms, isolated tympanic membrane perforation has not shown to be an indicator of more serious occult injuries such as blast lung injuries.[37] On the other hand, an intact

tympanic membrane following exposure to a blast does not exclude a pulmonary blast injury, particularly if the victim had been wearing some type of hearing protection, as is common in certain types of military or law enforcement operations.

Different parts of the ear can also be involved in secondary, tertiary and quaternary blast injuries resulting from penetrating traumata (discussed earlier), lateral skull base fractures and coup contrecoup injuries (Chapter 13), thermal and caustic injuries (discussed below) and noise (Chapter 12). The assessment and management of these ear traumata is discussed in more detail in the specific chapters and relevant paragraphs.

Pre-hospital assessment of blast injuries of the middle ear (fact sheet)

An early assessment strategy depends on the nature and extent of the blast injury. In case of high-order explosions with multiple causalities and explosions in the context of terrorist attacks, the pre-hospital life support systems and basic management according to the Tactical Combat Casualty Care for Medical Personnel (TCCC) guidelines (Chapter 3b) are the first priority.

In some victims, signs and symptoms of ear trauma are immediately visible or reported, e.g., bleeding from the ear, earache, hearing loss, tinnitus, vertigo and facial nerve palsy.

Hospital assessment and early management of blast injuries of the middle ear (fact sheet)

After basic lifesaving measures and severe injuries have been addressed, all patients exposed to a significant blast incident should be assessed otologically. During the course of their hospital stay, an audiometric evaluation is also mandatory.[38]

Bedside otoscopic evaluation is often inconclusive in the case of blast injuries due to blood clots, cerumen or debris obscuring a view of the eardrum. In a conscious patient, Weber and Rinne tuning fork tests are helpful to screen for hearing loss and to determine whether hearing loss is conductive or sensorineural. Facial nerve function is evaluated by testing facial expression. Management of facial baroparesis or facial nerve palsy due to secondary, tertiary or quaternary blast injuries are addressed in Chapters 12 and 13.

Otorhinolaryngologic referral allows for a thorough otomicroscopic evaluation through cleaning of the ear and removal of eventual debris, blood clots or foreign bodies. A detailed description of traumata of the external ear related to blast injuries and their treatment is given in Chapter 10.

Middle ear damage following blast insult include intratympanic haemorrhages, tympanic membrane rupture, middle ear bleeding and ossicular discontinuity and dislocation.[39]

Tympanic membrane perforation is the most common primary blast injury and can vary from single to multiple, from small to total and according to the shape of the laceration, may be smooth and linear, punched out, or ragged with edges inverted or everted. [40] The early management of tympanic membrane perforations is extensively discussed in the previous paragraph of this paper (blunt and penetrating injuries).

Particularly in the case of larger blasts, the ossicular chain can also be damaged. Blast trauma at the level of the ossicular chain is generally associated with a tympanic membrane rupture, but can in rare instances occur without tympanic membrane perforation. Fractures or disarticulation can occur at different and multiple levels of the ossicular chain and can sometimes be seen as the result of tympanic membrane perforation. The middle ear can also be contaminated or infected by fragments of the explosion, dirt or water entering the middle ear.

Inverted perforation edges should be carefully everted by suction or the use of a pick; in large perforations, visible epithelium fragments in the middle ear should be removed by irrigation with antibiotic drops and suction to increase the chances of healing, and to prevent the later formation of cholesteatoma (see paragraph 3.4).

A baseline audiometry in all blast-injured patients is advocated, since hearing deficits are common and not always noted by the patient.[38] Next to conductive hearing loss related to tympanic membrane perforation, middle ear haemorrhage and/or ossicular chain damage, many patients exposed to a blast develop sensorineural hearing loss caused by barotrauma or noise-related injury to the inner ear (Chapter 12 and 14).

In the case of vestibular symptoms associated with fluctuating or progressive sensorineural or mixed hearing loss, as well as often additional complaints of tinnitus, hyperacousis or aural fullness, a perilymphatic fistula at the level of the round and/or oval window should be expected. The latter can be

caused by the immediate effect of the blast wave on the oval or round window, but also by blast-induced fracture or dislocation of the stapes. A fistula test should be performed (Chapter 14).

Following primary blast trauma, penetrating trauma from projectiles through the outer ear, (see above, 'penetrating trauma') temporal bone fractures (Chapter 13) and thermal injuries (see below, 'thermal and caustic injuries') can also occur in the context of a blast trauma, and can lead to middle ear trauma involving the tympanic membrane and ossicular chain, as well as facial nerve damage.

Long-term follow-up, treatment and prognosis of blast injuries of the middle ear (fact sheet)

As in penetrating and blunt injuries, the treatment of tympanic membrane perforations is typically anticipated. Otomicroscopic and audiometric follow-up at regular intervals (six weeks, three months, six months following blast trauma) is recommended to observe spontaneous closure. Meanwhile, the ear should be kept dry and clean. If ossicular chain damage is suspected, a high resolution CT scan should be performed.

The probability of spontaneous closure of a tympanic membrane perforation due to blast injury is smaller than for tympanic membrane perforations, caused by penetrating trauma. Depending on the type and extent of the blast incident, between 30% and up to more than 70% spontaneous closure is reported.[41,42]

If no spontaneous closure of the tympanic membrane occurs after six months, a myringoplasty can be proposed, but can also be delayed until patients are physically and emotionally prepared for surgery. During surgical repair of the tympanic membrane, the integrity of the ossicular chain should also be carefully assessed and repaired if necessary.

In case of (suspected) ossicular chain damage with an intact or spontaneously closed tympanic membrane, elective exploratory tympanoplasty or hearing aid amplification should be offered to restore hearing loss. Middle ear surgery following blast injury is never urgent, except in patients with symptoms of a perilymphatic fistula that persist for one-to-two weeks after trauma.[1]

Following tympanic membrane rupture by a blast, small fragments of keratinizing squamous epithelia from the outer surface of the drum may be distributed throughout the middle ear, which may result in delayed formation of the cholesteatoma.[43] The cholesteatoma may present as a small keratin pearl, which is relatively easy to recognize and manage, but may also form an open epithelial "carpet", which is less distinct and more difficult to remove. The incidence of cholesteatoma following a primary blast injury of the middle ear ranges from 8-12%[43-45] (see Figure 3). For this reason, spontaneous healing of the perforation does not signal the end of follow-up. It is essential that a clinical follow-up be schedules every six months for a minimum of two years. Some authors advise performing standard imaging (diffusion weighted MRI) one-to-two years after a blast injury with tympanic membrane perforation.[13]

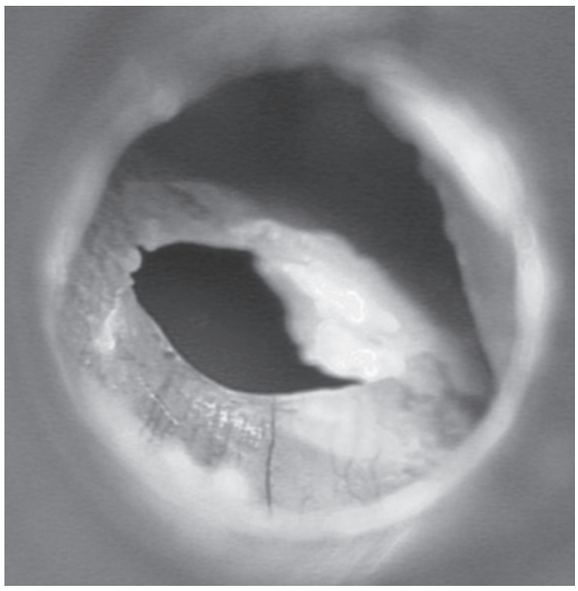

Figure 3

Cholesteatoma formation from the edges of a tympanic membrane perforation after blast trauma

Thermal and caustic injury of the middle ear

Thermal and caustic injuries are a rare cause of middle ear trauma. They can cause the same spectrum of middle ear trauma as penetrating injuries of the middle ear (tympanic membrane perforation, ossicular chain disruption, facial nerve injury), but occur in typical situations and can cause some challenging injuries, warranting a specific approach next to the basic evaluation and management principles of injuries to the tympanic membrane and middle ear.

Thermal injuries (frostbite and burns) of the ear primarily cause trauma to the outer ear; however, when hot projectiles enter the outer ear canal, they can also damage the tympanic membrane and middle ear. Typical causes of thermal middle ear lesions are drop weld injuries as the result of hot sparks or molten slag among steel workers and welders. A spectrum of severity of injury occurs, which includes primarily tympanic membrane perforation and middle ear inflammation, but facial nerve injury and ossicular chain disruption have also been described.[46] Welding injuries often result in non-healing perforations due to a combination of thermal injury to the tympanic membrane (the slag acts to cauterize or devascularize the tympanic membrane as it passes through it) and foreign body reaction due to the embedding of metal slag in the middle ear mucosa, resulting in continuing or recurrent suppuration (Figure 4). Early removal of these foreign bodies is extremely important for preventing chronic otitis media; however, this is not always straightforward, especially in the case of additional outer ear lesions and middle ear infection, which is preferentially first treated with local antibiotic drops, with or without cortisone. If anamnesis and clinical symptoms lead to the suspicion of having a (metallic) foreign body in the middle ear, CT imaging can be helpful for verifying the diagnosis and to localize the foreign body prior to surgical exploration. Transtympanic thermal trauma, however, is often a preventable occupational injury that can be avoided through the use of earplugs or ear muffs and increased awareness.[47]

Household or industrial caustic substances that accidently or non-accidently enter the outer ear canal can also cause a range of lesions. These involve (1) the outer ear, with risk of extensive scarification; (2) the tympanic membrane, potentially leading to (chronic) myringitis and poorly healing tympanic membrane perforation; (3) the middle ear, which can develop an extensive granulation reaction with scarification, ossicular fixation and chronic infection; (4) cases of facial nerve paralysis and profound cochleovestibular loss have also been described.[48] The most common cause of caustic injury to the middle ear results from button batteries accidently lodged in the outer ear and leaking battery acid, affecting surrounding soft tissue and bone and which can extend into the middle ear and mastoid. They damage tissue via pressure necrosis, low voltage burns and alkaline corrosion, and should be promptly removed.[49]

Figure 4
Tympanic membrane perforation by drop weld injury

Tympanic membrane perforations produced by heat, corrosives and welding injuries are not only less likely to heal spontaneously, but tympanoplasty also poses more surgical challenges with poorer outcomes. This is likely attributable to often-associated chronic middle ear inflammation, scarification and devascularization of the remaining tissue, with diminished blood supply to the recipient graft site.[50]

Conclusion

The middle ear, as part of the head-neck region, is often exposed to trauma. In acute multisystem and life-threatening injuries, middle ear trauma does not take high priority. However, traumatic lesions of the middle ear should nonetheless be suspected and recognized as early as possible. The history, physical examination and early assessment of hearing and vestibular function should provide the physician with adequate information for determining the extent of an injury. Attention should be paid to signs of ear injury such as discharge or bleeding from the ear canal, penetrating trauma or burns of the outer ear, retro-auricular haematoma and facial nerve palsy. Regular follow-up of middle ear trauma, particularly following a blast, is necessary for two years following the trauma. The ultimate treatment goal for these patients is an intact tympanic membrane and good hearing. Military personnel and persons performing in a safety function are typically more frequently exposed to situations

Fact sheet : Traumatic lesions of the middle ear

Pre-hospital assessment

- Standard trauma protocols and lifesaving measures should always be addressed first in the assessment and management of the trauma patient

Hospital assessment and early treatment

- The extent of injury needs to be assessed by good history. The history should focus on the mechanism of injury and pre-existing deficits like perforated eardrum or hearing loss.
- Physical examination after trauma consists of cranial nerve examination, otoscopy, assessment of the hearing and vestibular function
- If cerumen, blood clots, or foreign bodies obscure view of the eardrum, these should be carefully suctioned and cleaned. The extent and the location of the tympanic membrane perforation and the presence of blood or infection in the middle ear can be evaluated.
- Early management of tympanic membrane perforation consists of keeping the ear dry and clean and administrating antibiotic ear drops if the perforation is contaminated or if middle ear infection is already present.
- When hearing loss or vertigo is present meticulous auditory and vestibular examination should be performed as soon as possible after a trauma. Baseline audiometry in patients with blunt, penetrating or blast injury of the temporal bone or middle ear has been advocated because hearing deficits are common and not always noted by the patient
- In cases of early facial nerve palsy or suspicion of perilymphatic fistula computed tomography of the temporal bones is necessary

Follow up, further treatment and prognosis

- Treatment of tympanic membrane perforations is typically expectant
- Tympanic membrane perforations typically have a good prognosis with spontaneous resolution in the majority of cases, but poorer prognosis in blast, thermal and caustic perforations
- Tympanoplasty is indicated if spontaneous resolution is not observed after 6 months close observation
- In large conductive hearing losses or persisting conductive hearing loss after spontaneous tympanic membrane closure and resolution of hemotympanum, ossicular chain dislocation or fracture is suspected; elective tympanoplasty is indicated
- Any traumatic tympanic membrane perforation runs the risk of cholesteatoma formation; follow-up is indicated biannually for a minimum of two years

where traumatic lesions of the ears and hearing can occur. Good hearing is important for everyone, but in these professions, it is also part of the medical requirements. Prompt recognition of (middle) ear trauma and adequate referral is necessary and preventive measures such as wearing ear plugs or ear muffs should be taken in risk situations.

References

1. Mc Whorter AJ, Niparko J. Otologic and skull base injuries. In: McQuone Ea, Ed. *Emergencies of the Head and Neck*. Mosby, St Louis: 2000: 265-277.
2. Sun GH, Shoman NM, Samy RN, Cornelius RS, Koch BL, Pensak ML. Do contemporary temporal bone fracture classification systems reflect concurrent intracranial and cervical spine injuries? *Laryngoscope*. 2011;121(5):929-932.
3. Johnson F, Semaan MT, Megerian CA. Temporal bone fracture: evaluation and management in the modern era. *Otolaryngol Clin North Am*. 2008;41(3):597-618.
4. Bellucci RJ. Traumatic injuries of the middle ear. *Otolaryngol Clin North Am*. 1983;16(3):633-650.
5. Moore PL, Selby G, Irving RM. Gunshot injuries to the temporal bone. *J Laryngol Otol*. 2003;117(1):71-74.
6. Camnitz PS, Bost WS. Traumatic perforations of the tympanic membrane: early closure with paper tape patching. *Otolaryngol Head Neck Surg*. 1985;93(2):220-223.
7. Simsek G, Akin I. Early paper patching versus observation in patients with traumatic eardrum perforations: comparisons of anatomical and functional outcomes. *J Craniofac Surg*. 2014;25(6):2030-2032.
8. Lou ZC, He JG. A randomised controlled trial comparing spontaneous healing, gelfoam patching and edge-approximation plus gelfoam patching in traumatic tympanic membrane perforation with inverted or everted edges. *Clin Otolaryngol*. 2011;36(3):221-226.
9. Park MK, Kim KH, Lee JD, Lee BD. Repair of large traumatic tympanic membrane perforation with a Steri-Strips patch. *Otolaryngol Head Neck Surg*. 2011;145(4):581-585.
10. Jun HJ, Oh KH, Yoo J, Han WG, Chang J, Jung HH, Choi J. A new patch material for tympanic membrane perforation by trauma: the membrane of a hen egg shell. *Acta Oto-Laryngologica*. 2014;134(3):250-254.
11. Zhengcai L, Zihan L, Yongmei T. Comparative study on the effects of EGF and bFGF on the healing of human large traumatic perforations of the tympanic membrane. *Laryngoscope*. 2016;126(1):E23-28.
12. Keir J, Clarke R. A systematic review of concomitant interventions to prevent persistent perforations following the removal of long-term ventilation tubes. *Intern J Ped Otorhinolaryngol*. 2009;73(10):1321-1324.
13. Medina M, Dumon T. Cholesteatoma behind a normal tympanic membrane after trauma (Blast). *Rev Laryngol Otol Rhinol*. 2014;135(4-5):211-214.
14. Little SC, Kesser BW. Radiographic classification of temporal bone fractures: clinical predictability using a new system. *Arch Otolaryngol Head Neck Surgery*. 2006;132(12):1300-1304.
15. Hasso AN, Ledington JA. Traumatic injuries of the temporal bone. *Otolaryngol Clin North Am*. 1988;21(2):295-316.
16. Mafee MF, Valvassori GE, Kumar A, Yannias DA, Marcus RE. Pneumolabyrinth: a new radiologic sign for fracture of the stapes footplate. *Am J Otol*. 1984;5(5):374-375.
17. Lerut B, Pfammatter A, Moons J, Linder T. Functional correlations of tympanic membrane perforation size. *Otol Neurotol*. 2012;33(3):379-386.
18. Seltzer S, McCabe BF. Perilymph fistula: the Iowa experience. *Laryngoscope*. 1986;96(1):37-49.
19. Glasscock ME, 3rd, Hart MJ, Rosdeutscher JD, Bhansali SA. Traumatic perilymphatic fistula: how long can symptoms persist? A follow-up report. *Am J Otol*. 1992;13(4):333-338.
20. Kim SH, Kazahaya K, Handler SD. Traumatic perilymphatic fistulas in children: etiology, diagnosis and management. *Intern J Ped Otorhinolaryngol*. 2001;60(2):147-153.
21. Yanagihara N, Nishioka I. Pneumolabyrinth in perilymphatic fistula: report of three cases. *Am J Otol*. 1987;8(4):313-318.
22. Lao WW, Niparko JK. Assessment of changes in cochlear function with pneumolabyrinth after middle ear trauma. *Otol Neurotol*. 2007;28(8):1013-1017.
23. Kristensen S. Spontaneous healing of traumatic tympanic membrane perforations in man: a century of experience. *J Laryngol Otol*. 1992;106(12):1037-1050.
24. Jellinge ME, Kristensen S, Larsen K. Spontaneous closure of traumatic tympanic membrane perforations: observational study. *J Laryngol Otol*. 2015;129(10):950-954.
25. Lou ZC, Lou ZH, Zhang QP. Traumatic tympanic membrane perforations: a study of etiology and factors affecting outcome. *Am J Otolaryngol*. 2012;33(5):549-555.
26. Lou ZC, Tang YM, Yang J. A prospective study evaluating spontaneous healing of aetiology, size and type-different groups of traumatic tympanic membrane perforation. *Clin Otolaryngol*. 2011;36(5):450-460.
27. Araujo MM, Murashima AA, Alves VM, Jamur MC, Hyppolito MA. Spontaneous healing of the tympanic membrane after traumatic perforation in rats. *Braz J Otorhinolaryngol*. 2014;80(4):330-338.
28. Yetiser S, Hidir Y, Birkent H, Satar B, Durmaz A. Traumatic ossicular dislocations: etiology and management. *Am J Otolaryngol*. 2008;29(1):31-36.
29. Wolf SJ, Bebarta VS, Bonnett CJ, Pons PT, Cantrill SV. Blast injuries. *Lancet*. 2009;374(9687):405-415.
30. Mathews ZR, Koyfman A. Blast Injuries. *J Emerg Med*. 2015;49(4):573-587.
31. Marks M, Ed. *The Emergency Responder's Guide to Terrorism: a Comprehensive Real-World guide to Understanding Terrorist Weapons of Mass Destruction*. Red Hat Publishing Company, Chester: 2002.
32. Hexdall A, Miglietta M.A. Mechanism of injury. In: Legome E, Shockley LW, Eds. *Trauma: A Comprehensive Emergency Medicine Approach*. Cambridge University Press, New York, 2011:24-34.
33. Breeze J, Cooper H, Pearson CR, Henney S, Reid A. Ear injuries sustained by British service personnel subjected to blast trauma. *J Laryngol Otol*. 2011;125(1):13-17.
34. Mellor SG, Cooper GJ. Analysis of 828 servicemen killed or injured by explosion in Northern Ireland 1970-84: the Hos-

tile Action Casualty System. *Br J Surg*. 1989;76(10):1006-1010.
35. Garth RJ. Blast injury of the ear: an overview and guide to management. *Injury*. 1995;26(6):363-366.
36. Telischi FF, Patete ML. Blast injuries to the facial nerve. *Otolaryngol Head Neck Surg*. 1994;111(4):446-449.
37. Leibovici D, Gofrit ON, Shapira SC. Eardrum perforation in explosion survivors: is it a marker of pulmonary blast injury? *Annals Emerg Med*. 1999;34(2):168-172.
38. Centre for disease control, USA. Explosions and Blast Injuries A Primer for Clinicians. Available at: http://www.cdc.gov/masstrauma/preparedness/primer.pdf. Accessed February 7, 2016.
39. Kerr AG. Trauma and the temporal bone. The effects of blast on the ear. *J Laryngol Otol*. 1980;94(1):107-110.
40. Pahor AL. The ENT problems following the Birmingham bombings. *J Laryngol Otol*. 1981;95(4):399-406.
41. Remenschneider AK, Lookabaugh S, Aliphas A, Brodsky JR, Devaiah AK, Dagher W, Grundfast KM, Heman-Ackah SE, Rubin S, Sillman J, Tsai AC, Vecchiotti M, Kujawa SG, Lee DJ, Quesnel AM. Otologic outcomes after blast injury: the Boston Marathon experience. *Otol Neurotol*. 2014;35(10):1825-1834.
42. Tungsinmunkong S, Chongkolwatana C, Piyawongvisal W, Atipas S, Namchareonchaisuk S. Blast injury of the ears: the experience from Yala Hospital, Southern Thailand. *J Med Assoc Thai*. 2007;90(12):2662-2668.
43. Kronenberg J, Ben-Shoshan J, Modan M, Leventon G. Blast injury and cholesteatoma. *Am J Otol*. 1988;9(2):127-130.
44. Sridhara SK, Rivera A, Littlefield P. Tympanoplasty for blast-induced perforations: the Walter Reed experience. *Otolaryngol Head Neck Surg*. 2013;148(1):103-107.
45. Seaman RW, Newell RC. Another etiology of middle ear cholesteatoma. *Arch Otolaryngol*. 1971;94(5):440-442.
46. Keogh IJ, Portmann D. Drop weld thermal injuries to the middle ear. *Rev Laryngol Otol Rhinol*. 2009;130(4-5):317-319.
47. Lukan N. Burn injuries of the middle ear. ORL; *J ORL Rel Spe*. 1991;53(3):140-142.
48. Wolter NE, Cushing SL, Das-Purkayastha PK, Papsin BC. Non-accidental caustic ear injury: two cases of profound cochleo-vestibular loss and facial nerve injury. *Intern J Pediat Otorhinolaryngol*. 2012;76(1):145-148.
49. Skinner DW, Chui P. The hazards of 'button-sized' batteries as foreign bodies in the nose and ear. *J Laryngol Otol*. 1986;100(11):1315-1318.
50. Lasak JM, Van Ess M, Kryzer TC, Cummings RJ. Middle ear injury through the external auditory canal: a review of 44 cases. *Ear Nose Throat J*. 2006;85(11):722, 4-8.

Dr Helen Van Hoecke, M.D.
Department of Otorhinolaryngology
Ghent University Hospital
De Pintelaan 185
B-9000 Ghent
Belgium
Tel.: 0032 9332 23 32
Fax: 0032 9332 49 93
Email: helen.vanhoecke@UGent.be